

Silflex[®]

Soft silicone wound contact layer



Soft and gentle



Hospitals Trust Defries

t: 03 9706 3600 freecall: 1300 550 278
e: sales@defries.com.au www.defries.com.au


Advancis

Medical

www.advancis.co.uk

Silflex®

Soft silicone wound contact dressing



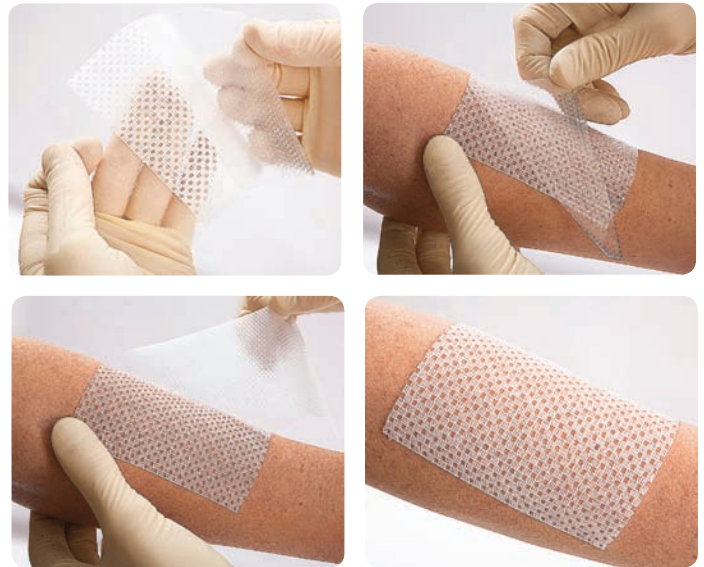
Product description

An atraumatic, soft silicone wound contact layer designed to prevent secondary dressings adhering to fragile skin and delicate wound beds.

Silflex® is designed to gently adhere to the skin surrounding a wound and not to the wound bed. This is an atraumatic dressing which means it is designed to minimise the pain and trauma associated with dressing change. The dressing allows the passage of exudate.

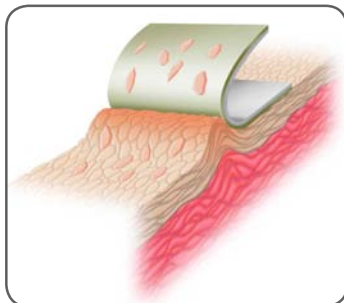
Dressing features and benefits

- ✓ *Atraumatic, silicone dressing for pain free removal*
- ✓ *Lower priced in comparison to other market leading brands, fitting with budget constraints*
- ✓ *Large range of sizes for simplified dressing selection*
- ✓ *Can be cut to size (ensuring sharp scissors are used)*
- ✓ *Hydrophobic silicone coating prevents the dressing adhering to the wound bed*
- ✓ *Highly conformable for increased patient compliance*
- ✓ *Unique large dressing size, 60cm x 35cm*
- ✓ *Large open pores reduce the potential for clogging and pooling underneath the dressing, allowing exudate to pass through*



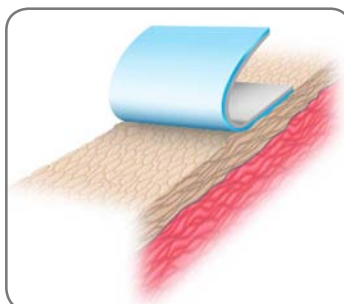
Why soft silicone?

Pain at dressing change is a major issue within wound care. Traditional adhesives can damage newly formed tissue or surrounding skin delaying healing and causing pain to the patient.



Traditional adhesive dressings

- *Traditional adhesives easily damage or strip these cells when removed*
- *Unflexible by nature they touch only the highest points of the skins surface, therefore they fix more strongly to small areas*
- *Almost impossible to reposition once applied*



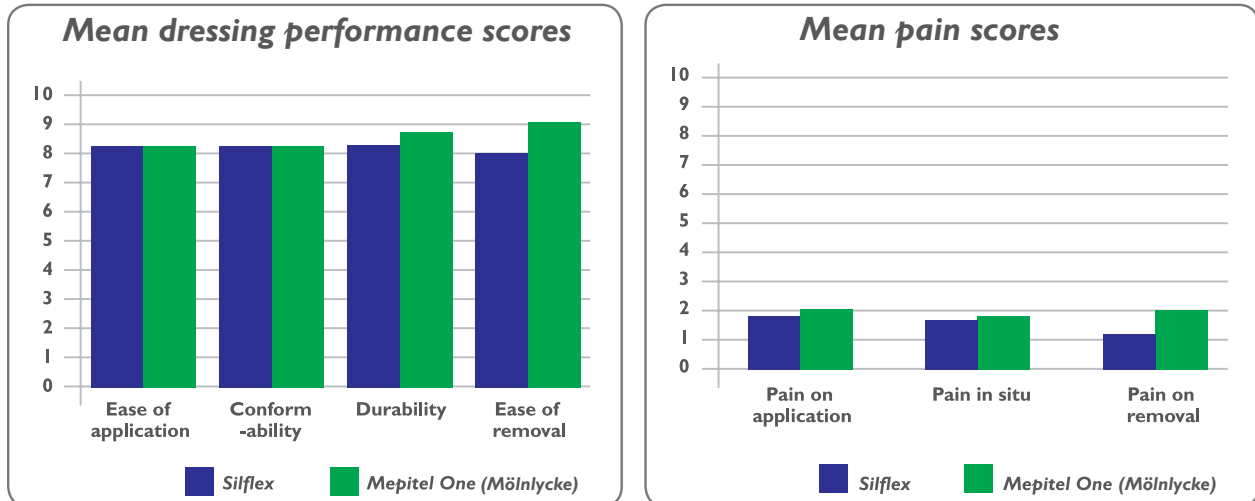
Soft silicone dressings

- *Gently adheres to the dry skin but not to a moist wound*
- *The gentle adhesion prevents skin stripping and damage to healthy tissue at dressing change*
- *Allows for easy, pain free removal minimising patient stress and discomfort*

Silflex[®] and burns

The treatment of burn wounds is complex and the correct dressing selection can have a huge impact on the time taken for the wound to heal. With correct management, dressings can speed up the healing process and prevent the formation of problematic scars.

Comparative Wound Contact Layer Dressing Evaluation



Taken from 'Developing a structured process for evaluating burn dressings' by Jacky Edwards - Burns Nurse Consultant & Sally Ann Mason - Burns Outreach Sister (Wythenshawe Hospital, Manchester)

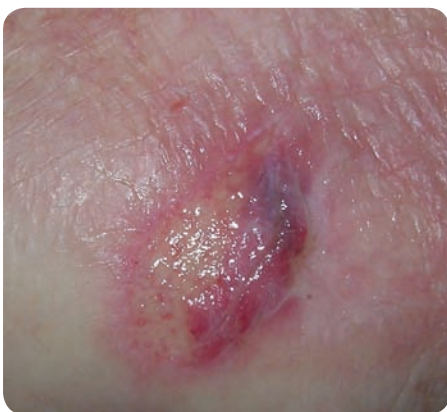Pain during dressing changes has been shown to have detrimental effects on patients which then impacts on quality of life. A study by Timmons et al (2009) found that the use of silicone dressings improved patients quality of life by reducing pain on removal, reducing anxiety and ultimately, speeding up the healing process.

Case reports

Taken from 'Case reports using Silflex soft silicone wound contact dressing' Supplement, Wounds UK, 2010

This case report features an 80-year-old man who was admitted to a care of the elderly ward following an extension of a cerebral vascular accident (CVA). He also had a history of Crohn's disease and Parkinson's disease. He was restricted to bed and had difficulty with eating and communicating.

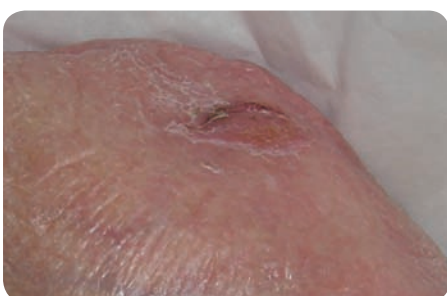Review 1:



The patient was admitted to the ward with a small skin tear on his left arm, which had a scant covering of yellow slough. The tear measured 2 x 1.2cm and was exuding very high volumes of serous exudate.

On examination, the patient's upper body, in particular his arms, were very oedematous and leaking from small points. Silflex[®] non-adherent silicone was applied in order to prevent any trauma to the wound itself or the surrounding tissue. Due to the extensive nature of the exudate, a large absorbent dressing pad was used as a secondary dressing and secured with a light non-elastic bandage. It was suggested that the pad and bandage be changed according to the level of exudate, but that the Silflex[®] should be left in situ for 2–3 days. The ward staff carried out this plan.

Review 2:

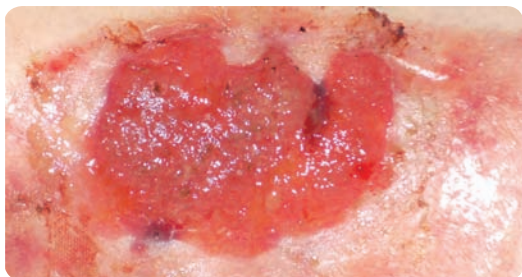


Six days later and after three primary dressing changes, the wound had completely healed. The patient's general health had also improved — he was more stable medically and the fluid that was overloading his system had reduced once he had been started on the appropriate diuretic.

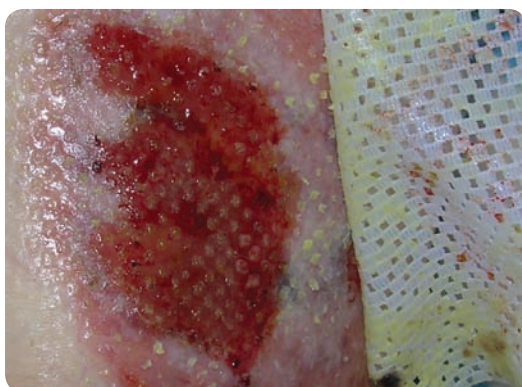Conclusion:

The use of Silflex[®] provided a primary dressing for the skin tear on this patient's very friable tissue. Serous fluid was able to drain into the secondary dressing pad, preventing maceration of the surrounding tissue. The wound was able to heal well and quickly.

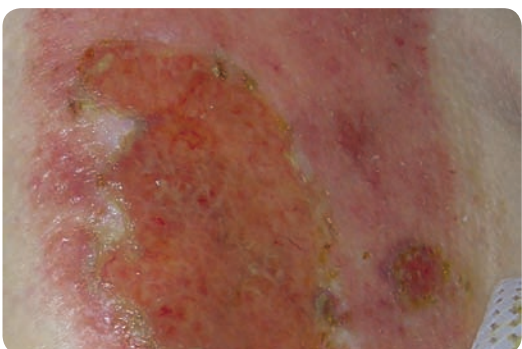
This 91-year-old woman was referred due to a longstanding leg ulcer which had taken a skin graft six months before referral. The skin graft had not been successful and the donor site had failed to heal completely.



The donor site has partially healed leaving an area of 6 x 6cm of hypergranulation. This area had been treated using Acticoat™ (Smith and Nephew) for four weeks before review. The wound was painful and bled when touched. At this point the decision was taken to treat the hypergranulation while protecting the fragile new epithelium which covered the remainder of the donor site.



The hypergranulation was treated daily for seven days with Terracortil ointment (Pfizer) and the wound was covered with Silflex®. As the ointment needed to be applied daily, a silicone dressing was required to prevent damage to the fragile tissue. An absorbent dressing was used to cover this and secured using yellow line Comfast.



Following three days of treatment the wound was reviewed to establish if the daily dressings were causing trauma to the periwound area or the wound bed. On inspection, it was seen that the hypergranulation was beginning to resolve and the periwound area was in good health with no evidence of skin stripping or trauma. At this point the wound was still 6 x 6cm. The patient reported no pain or trauma at dressing changes.

Conclusion:

After eight days and eight dressing changes the hypergranulation had resolved and the periwound area remained intact. The patient had not found the dressing changes painful.



Scan me for more information



Stock code	Size	PIP code	NHS code	Dressings per box
CR3922	5cm x 7cm	338-4385	EKH028	10
CR3923	8cm x 10cm	338-4393	EKH029	10
CR3924	12cm x 15cm	338-4401	EKH030	10
CR3925	20cm x 30cm	338-4419	EKH032	10
CR4006	35cm x 60cm	348-2205	n/a	5

Defries Industries
Hospitals Trust Defries

t: 03 9706 3600 freecall: 1300 550 278
e: sales@defries.com.au www.defries.com.au

Advancis
Medical
www.advancis.co.uk

Lowmoor Business Park, Kirkby-in-Ashfield
Nottingham, NG17 7JZ, England

Tel: +44 (0)1623 751500 | Fax: +44 (0)871 264 8238 | Email: info@advancis.co.uk

MAR208/r1